

Calcifying Fibrous Tumor Present as Small Bowel Obstruction: Case Report

Safi khuri^{1*}, Sobhi Mansor¹, Yoram Kluger^{1,2} and Bishara bishara^{1,3}

¹Department of General Surgery, Rambam Health Campus, Haifa, Israel.

²Hepato-pancreatico-biliary and surgical oncology unit

³Minimally invasive unit

*Corresponding author

Safi Khuri, Department of General Surgery, Rambam Health Campus, Haifa, Israel, Email: s_khuri@rambam.health.gov.il

Submitted: 05 Sep 2017; Accepted: 12 Sep 2017; Published: 28 Sep 2017

Abstract

Calcifying fibrous tumor is a rare benign mesenchymal tumor that usually affect children and young adults. This tumor is usually solitary, with unknown etiology. It usually arise in the extremities and trunk. Gastrointestinal involvement is very rare. Herein, we present a case of a 24 year old male patient who was diagnosed with calcifying fibrous tumor presented as small bowel obstruction.

Keywords: Calcifying Fibrous Tumor, Gastrointestinal Tract.

Introduction

Calcifying fibrous tumor (CFT) is a rare, benign soft tissue tumor arise from fibrous connective tissues. It was first described as “childhood fibrous tumor with psammoma bodies” in 1988 by Rosenthal and Abdul-Karim, and later termed “calcifying fibrous pseudo-tumor” by Fetsch and colleagues [1,2]. CFT is usually solitary and its exact pathogenesis is unknown. This tumor mostly involve the soft tissues of the extremities, pleura or peritoneum [3,4]. Involvement of the gastrointestinal (GI) tract is rare, and most data are based on single case reports [5]. Herein, we present a case of 24 year old male patient presented with small bowel obstruction. At surgery, a well-circumscribed mass at the mid ileum attached to a fibrotic band was demonstrated as the cause of small bowel obstruction. En block resection was performed. Pathology report was positive for calcifying fibrous tumor.

Case presentation

A 24-year-old healthy male patient presented to our emergency department with diffuse abdominal pain of acute onset. The pain lasted for 7 hours, started abruptly, and was described as a colicky in nature. He also complained of nausea, recurrent vomiting and constipation of 3 days duration. Upon examination, his vital signs were within normal limits. The abdominal examination revealed a distended abdomen, with slight diffuse tenderness and high pitched bowel sounds by auscultation. Digital rectal exam revealed an empty rectal ampulla. Complete blood count showed increased white blood cells of 16000. Liver and kidney function tests were within normal limits. An upright abdominal x-ray showed multiple air-fluid levels, and supine abdominal x-ray revealed a dilated bowel loops; compatible with small bowel obstruction. A computed tomography scan showed a spherical mass of 1.6 cm at the level of sacral promontorium, with scattered calcifications, leading to small bowel obstruction, with proximal dilation of bowel loops to a 5 cm diameter (**Figure 1**). A moderate amount of free intra-abdominal fluid was also demonstrated. He was admitted with a diagnosis of small intestinal obstruction.

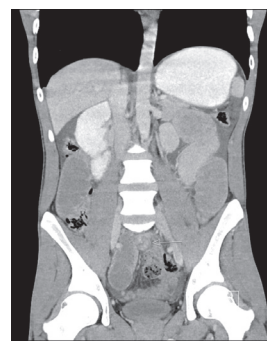


Figure 1: coronal CT scan showed a well circumscribed mass with calcifications (arrow) and dilated bowel loops.

Due to the aforementioned findings, the patient underwent a diagnostic laparoscopy, during which a well-circumscribed, white colored spherical, firm mass, located at the mid ileum, was found, attached to a fibrotic band, and causing intestinal obstruction at the level of the nearby bowel loop (**Figure 2**). A moderate amount of serous fluid was also demonstrated. Adhesiolysis of the fibrotic band, and En block resection of the mass, along with a 10 cm of mid ileum was done, and primary side-side anastomosis was performed. A wound protector during extraction of the specimen was used. Inspection of the rest of the abdominal cavity did not reveal an associated abnormalities. His postoperative period was uneventful, and the patient discharged home on postoperative day 4.

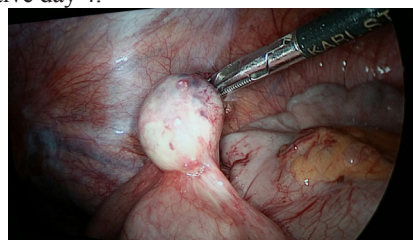


Figure 2: by Diagnostic laparoscopy, a well-circumscribed, white colored spherical mass arising at the mid ileum was revealed.

The histopathological examination of the specimen showed a calcifying fibrous tumor of 2 cm diameter, made of fibrous connective tissue with collagen, spindle cells and psammomatous calcification. Immunohistochemically, tumor cells were positive for vimentin and factor XIIIa, and negative for desmin, actin and factor VII. These findings are compatible with a diagnosis of calcifying fibrous tumor. Sixteen months postoperatively, the patient is doing well, with no evidence of disease recurrence.

Discussion

CFT is a benign mesenchymal tumor, usually affect children and young adults [6]. In children and adolescents, it usually arise in the subcutaneous tissues of the extremities, while in young adults, it can also involve the pleura cavity, mediastinum, gastrointestinal tract, liver and retroperitoneal space [5,7,8]. Although it can present as a multifocal lesion, it is usually diagnosed as a single mass [6]. CFT is usually asymptomatic and discovered incidentally. Small tumors that involve the GI tract are usually asymptomatic, while large tumors are symptomatic. Symptoms are usually related to the size and location of the primary tumor, with the most common presenting symptoms being chronic abdominal pain, abdominal distension and a palpable mass [6]. The most commonly involved GI site by CFT are the stomach, which can present as a gastric ulcer, and the small intestine, which can present as small bowel obstruction [3,9-12]. CFTs involving the GI tract usually arise in the sub mucosa layer, and the average tumor size is 2.6 cm [13]. Macroscopically, these tumors are well-circumscribed, spherical white-gray mass, non-encapsulated with a firm consistency. Microscopically, CFTs have a distinguished characteristics, including low cell count of collagenized fibrous connective tissues, spindle cells, inflammatory cell infiltrate and psammomatous calcifications [4,5]. Despite advances in imaging studies, pre-operative diagnosis is usually difficult. Computed tomographic characteristics of CFT include well-circumscribed homogenous mass with scattered calcifications [14,15,16].

Differential diagnosis of CFT of the GI tract include other mesenchymal tumors, such as gastrointestinal stromal tumor (GIST) and desmoid tumor, inflammatory myofibroblastic tumors and solitary fibrous tumor [4]. Discrimination between these tumors is very important, due to the fact that they have different biological behavior and different therapeutic strategies.

The diagnosis of CFT is usually based on histopathological and immunohistochemical examinations [6]. Tumor cells stain strongly positive for factor XIIIa and vimentin [17,18]. Reactivity to CD 31, CD 34 and SMA is partially positive, and reactivity to other immunostains as factor VII, desmin and smooth muscle actin are negative [19]. CFT is usually benign tumor, without malignant potential and thus, do not metastasize. Treatment by surgical resection of the tumor along with negative margins is the main treatment [20]. Local recurrence rate is approximately 10%; thus, a clinical follow up is warranted.

Conclusion

CFT of the GI tract is very rare, yet known tumor. Preoperative diagnosis by imaging studies is usually difficult, and a high index of suspicion is warranted, especially in young patients. Surgical management by means of resection with a negative margins is effective, with good tumor prognosis.

References

1. Rosenthal NS, Abdul-Karim FW (1988) Childhood fibrous tumor with psammoma bodies: clinicopathologic features in two cases. *Arch Pathol Lab Med* 112: 798-800.

2. Fetsch JF, Montgomery EA, Meis JM (1993) Calcifying fibrous pseudotumor. *Am J Surg Pathol* 17: 502-508.
3. Chen K (2003) Familial peritoneal multifocal calcifying fibrous tumor. *Am J Clin Pathol* 119: 811-815.
4. Emanuel P, Qin L, Harpaz N (2008) Calcifying fibrous tumor small intestine. *Ann Diagn Pathol* 12: 138-141.
5. Jo BJ, Yoon SW, Ahn HJ, Kwon SW (2011) Imaging findings of calcifying fibrous tumour of the liver. *Br Radiol* 84: 31-34.
6. Paszkiewicz I, Izycka E (2014) calcifying fibrous pseudotumor of the small bowel mesentery-case report. *POLSKI PRZEGLĄD CHIRURGICZNY* 86: 293-296.
7. Isaka M, Nakagawa K, Ohde Y, Okumura T, Kondo H, et al. (2011) Disseminated calcifying tumor of the pleura: review of the literature and a case report with immunohistochemical study of its histogenesis. *Gen Thorac Cardiovasc Surg* 59: 579-582.
8. Chang JW, Kim JH, Meeng YH (2011) Calcifying fibrous pseudotumor of anterior mediastinum. *Korean J Thorac Cardiovasc Surg* 44: 318-320.
9. Kocova L, Michal M, Sulc M, Zamecnik M (1997) Calcifying fibrous pseudotumour of visceral peritoneum. *Histopathology* 31: 182-184.
10. Azam M, Husen YA, Pervez S (2009) Calcifying fibrous pseudotumor in association with hyaline vascular type Castleman's disease. *Indian J Pathol Microbiol* 52: 527-529.
11. Agaimy A, Bihl MP, Tornillo L (2010) Calcifying fibrous tumor of the stomach: clinicopathologic and molecular study of seven cases with literature review and reappraisal of histogenesis. *Am J Surg Pathol* 34: 271-278.
12. Van Dorpe J, Ectors N, Geboes K, D'Hoore A, Sciote R (1999) Is calcifying fibrous pseudotumor a late sclerosing stage of inflammatory myofibroblastic tumor? *Am J Surg Pathol* 23: 329-335.
13. Larson B (2015) calcifying fibrous tumor of the gastrointestinal tract. *Arch Pathol Lab Med* 139.
14. Fan SF, Yang H, Li Z, Teng GJ (2010) Gastric calcifying fibrous pseudotumour associated with an ulcer: report of one case with a literature review. *Br J Radiol* 83: 188-191.
15. Jang KY, Park HS, Moon WS, Lee H, Kim CY (2012) Calcifying fibrous tumor of the stomach: a case report. *J Korean Surg Soc* 83: 56-59.
16. Giardino AA, Ramaiya NH, Shinagare AB, Jagannathan JP, Stachler MD, et al. (2011) Case report: calcifying fibrous tumor presenting as an asymptomatic pelvic mass. *Indian J Radiol Imaging* 21: 306-308.
17. Delbecq K, Legrand M, Boniver J, Lauwers GY, de Laval L (2004) Calcifying fibrous tumour of the gastric wall. *Histopathology* 44: 399-400.
18. Elpek GO, Kuşpesiz GY, Ögür M (2006) Incidental calcifying fibrous tumor of the stomach presenting as a polyp. *Pathol Int* 56: 227-231.
19. Montgomery E (2002) Calcifying fibrous tumor. In: Fletcher CD, Unni KK. *World Health Organization classification of tumors. Pathology and genetics of tumors of soft tissue and bone* 77-78.
20. Nascimento AF, Ruiz R, Hornick JL, Fletcher CD (2002) Calcifying fibrous 'pseudotumor': clinicopathologic study of 15 cases and analysis of its relationship to inflammatory myofibroblastic tumor. *Int J Surg Pat* 10: 189-196.

Copyright: ©2017 Safi Khuri. This is an open-access article distributed under the terms of the Creative Commons Attribution License, which permits unrestricted use, distribution, and reproduction in any medium, provided the original author and source are credited.